

# A systematic approach to full-mouth reconstruction of the severely worn dentition

Jay Lerner demonstrates a procedure that allows the clinician to obtain the space required for the restoration of severely worn dentition

**A**esthetic and functional restoration of the severely worn dentition represents a significant clinical challenge. One of the most demanding aspects of such cases involves the development of sufficient restorative space, while simultaneously fulfilling aesthetic, occlusal, and functional parameters essential to long-term success. When evaluating and diagnosing a patient with severely worn dentition, emphasis must be placed on the occlusal prematurities preventing condylar seating into the centric relation position. Success in maintaining severe wear cases depends on the development of proper anterior guidance to allow for posterior disclusion within the patient's envelope of function.

Restoration of the severely worn dentition is one of the most challenging procedures in dentistry. In order to successfully restore and maintain the teeth, one must gain insight into how the teeth arrived at this state of destruction. Tooth wear can result from abrasion, attrition, and erosion (Addy and Shellis 2006, Beyth et al 2006, Grippo et al 2004, Verrett 2001, Litonjua et al 2003). Research has shown that these wear mechanisms rarely act alone and there is nearly always a combination of the processes.



Dr. Lerner graduated from Columbia University School of Dentistry and completed a General Practice residency at Brookdale Medical Center in New York. He maintains a private practice in Palm Beach Gardens, Florida in which the focus is comprehensive restorative and aesthetic dentistry. Dr. Lerner is dedicated to continuing education having completed advanced training in aesthetic and restorative dentistry at Baylor College of Dentistry and New York University. He serves as a senior clinical instructor with the Rosenthal Institute at New York University, Guy's Hospital, London, England and the Palm Beach Community College in West Palm Beach. He is also the Chairman of the Comprehensive Esthetic and Restorative clinic at the Atlantic Coast Dental Research Clinic in West Palm Beach. Dr Lerner has published numerous articles for leading dental journals and lectures both nationally and in the United Kingdom. He can be reached at Jay Lerner, DDS, 5602 PGA Boulevard, Suite 201, Palm Beach Gardens, FL 33418, USA Tel: 001 561 627 9000 email: lernerjemongello@aol.com

comprehensive restorative and aesthetic dentistry. Dr. Lerner is dedicated to continuing education having completed advanced training in aesthetic and restorative dentistry at Baylor College of Dentistry and New York University. He serves as a senior clinical instructor with the Rosenthal Institute at New York University, Guy's Hospital, London, England and the Palm Beach Community College in West Palm Beach. He is also the Chairman of the Comprehensive Esthetic and Restorative clinic at the Atlantic Coast Dental Research Clinic in West Palm Beach. Dr Lerner has published numerous articles for leading dental journals and lectures both nationally and in the United Kingdom. He can be reached at Jay Lerner, DDS, 5602 PGA Boulevard, Suite 201, Palm Beach Gardens, FL 33418, USA Tel: 001 561 627 9000 email: lernerjemongello@aol.com

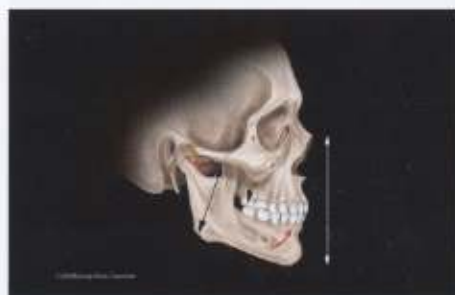

Figure 1: Posterior prematurities can cause the mandible to close in a position forward of centric relation

Evaluation and diagnosis should account for the patient's diet, history of eating and/or gastric disorders, along with the present state of the occlusion. Emphasis must be placed on the evaluation of occlusal prematurities preventing condylar seating into the centric relation position (Dawson 2006). Behavioural factors that may contribute to parafunctional habits and/or nocturnal bruxism are also important to understand and manage in order to successfully restore and maintain a healthier dentition (Neff 1995). Once a complete understanding of the etiology of the dentition's present state is appreciated, a treatment plan can be formulated, taking into account the number of teeth to be treated, condylar position, space availability, the vertical dimension of occlusion (VDO), and the choice of restorative material (Dahl et al 1993).

While all occlusions wear to some degree over the lifetime of the patient, normal physiological wear usually does not require correction (Dawson 2006). Severe or excessive wear refers to tooth destruction that requires restorative intervention. Severe attritional wear can result from occlusal prematurities that prevent functional or parafunctional movements of the jaw. This wear can be seen at the site of the prematurity or on the anterior teeth as a result of the 'hit and slide' forward (Dawson 2006). Restoration of the worn anterior teeth then becomes a challenge as space availability for prosthetics becomes limited. If lengthening the teeth is a goal in order to achieve a more aesthetic smile, then the question of the need to alter VDO subsequently arises.

There is some debate among professionals as to what constitutes the need to open VDO in the restoration of anterior teeth (Spear 2006).

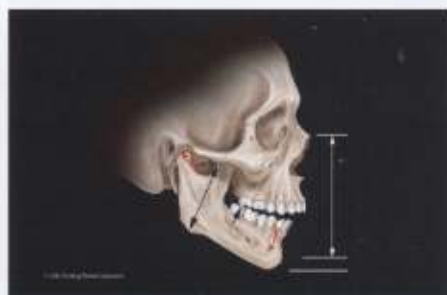

Figure 2: When the condyles are seated in centric relation, posterior teeth act as a fulcrum to prevent contact with the anterior teeth

In most cases, clinicians look to alter vertical dimension for one or all of the following reasons: to gain space for the restoration of the teeth; to improve aesthetics; or to correct occlusal relationships. Understanding what determines the VDO and what the effects of altering it have on the temporomandibular joint (TMJ), muscle comfort, bite force, speech, and long-term occlusal stability are prerequisites to restoring the worn dentition. Spear clearly outlines the principles of VDO and concludes that patients can function at many acceptable vertical dimensions, provided the condyles are functioning from centric relation and the joint complex is healthy. He states that 'vertical is a highly adaptable position, and there is no single correct vertical dimension.' He further concludes that the best vertical dimension is the one that satisfies the patient's aesthetic desires and the practitioner's functional goals with the most conservative approach (Spear 2006).

Vertical dimension is developed by the balance of ramus growth and tooth eruption (Spear 2006), and is affected by the repetitive contracted length of the elevator muscles during growth and development. It is, therefore, generally measured by a point on the maxilla and a point on the mandible at the area of first molars. Often, due to posterior prematurities the muscles of mastication are in a state of imbalance and will close the mandible in a position that is not in alignment with centric relation due to accommodation of the teeth (Sesemann 2005). This position is usually forward of centric relation (Figure 1).

Clinical examination of this condition will reveal anterior tooth wear with minimal posterior wear. When the condyles are seated in the

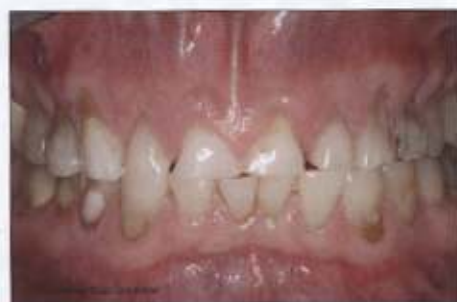

Figure 3: Preoperative view of a patient who presented with severely worn dentition

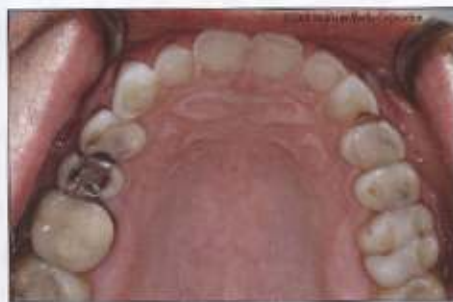

Figure 4: Bonded restorations were present on the lingual aspect of the maxillary anterior teeth, originally placed to restore a combination of attrition and erosion

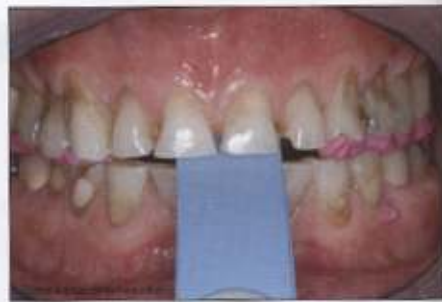

Figure 5: A centric relation bite record was performed with the use of a leaf gauge

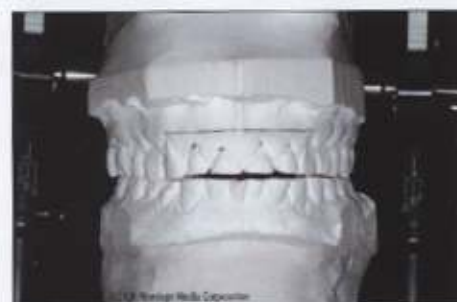

Figure 6: Mounted study casts revealed the second molars to be in premature contact when the condyles were seated in centric relation

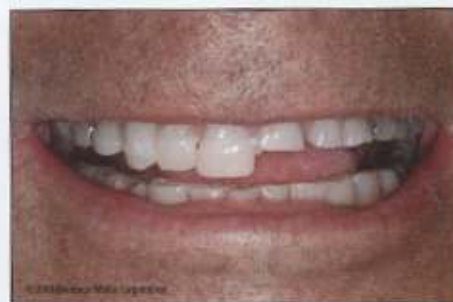

Figure 7: An intraoral composite mockup was performed to establish the ideal length for the central incisors

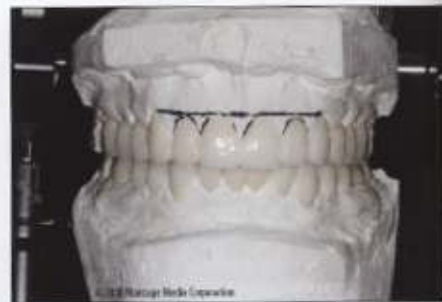

Figure 8: The full-mouth diagnostic waxup took into account that the second molars would be removed and aesthetic crown-lengthening procedures performed

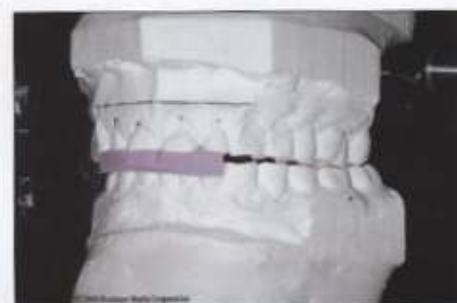

Figure 9: The ceramist fabricated a centric relation anterior index that held the centric relation position at the desired vertical dimension

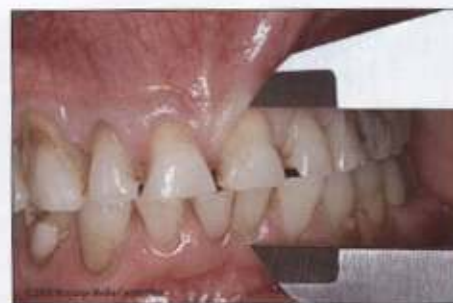

Figure 10: Measurement of the anterior space from marginal tissue of teeth # 9(21) through #24(31) (14.64mm) in maximum intercuspation

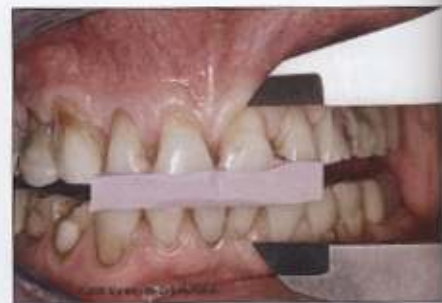

Figure 11: By seating the condyles, a gain of 2.38mm in anterior space was achieved without appreciably stretching the elevator muscles

centric relation position and the teeth come together, the posterior teeth act as a fulcrum that prevents the anterior teeth from touching (Figure 2). This anterior separation may provide enough space for the clinician to restore the aesthetic requirements of tooth length while maintaining a position that allows restoration of maximum intercuspation in conjunction with centric relation (Sesemann 2005).

When starting from a centric relation position, opening of the anterior teeth by 3mm will yield a posterior separation of approximately 1mm and stretch the masseter muscle length approximately 1mm. If the condyles are not in centric relation and are subsequently seated to a more superior position, every millimeter of vertical seating will reduce the masseter

muscle length by 1mm (Spear 2006) thereby eliminating the need for a true opening of vertical dimension. The following case presentation demonstrates a means to obtain the space required for the restoration of severely worn dentition without altering the VDO.

### Case presentation

A 55-year-old male patient presented with the chief complaint of anterior tooth wear and requested aesthetic enhancement (Figure 3). Clinical examination revealed severely worn anterior teeth and premolars in addition to bonded restorations on the lingual aspects of the maxillary anterior teeth to restore what appeared to be an erosive process. Advanced abrasion and or erosion were present on many

buccal surfaces of the canines and premolar teeth (Figure 4). The patient related a history that included clenching, grinding, and, as a young man, gastric regurgitation. His periodontal status included areas of posterior pocketing with advanced bone loss in the second molar regions. The gingiva also exhibited areas of clefting in the anterior regions.

In order to properly diagnose the case, a comprehensive examination was conducted, inclusive of a full-mouth radiographic series, caries detection, and periodontal probing. Evaluation of the TMJs was unremarkable, with normal jaw opening and range of motion. No joint sounds, signs or symptoms of instability were evident. Joint loading in centric relation was performed utilising bimanual

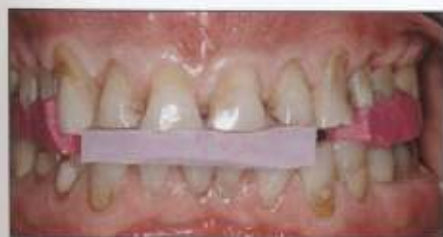

Figure 12: Preparation of the maxillary posterior teeth was performed using the index, and posterior bites were taken

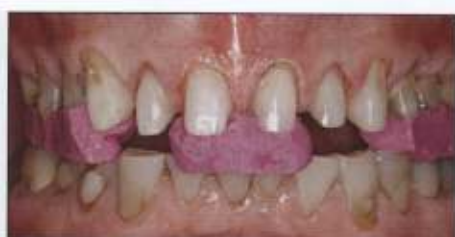

Figure 13: Anterior bite record taken with posterior bite records in place, maintaining the desired centric relation and VDO position

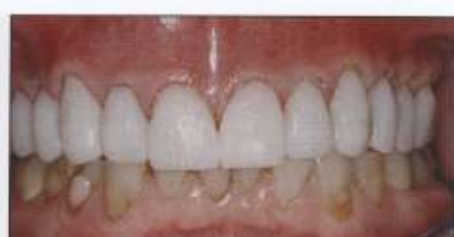

Figure 14: The provisional restorations were placed with petroleum jelly, in order to facilitate simple removal the following day

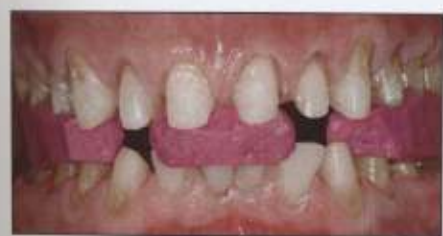

Figure 15: The mandibular posterior teeth were prepared with the anterior bite records from day one in place to hold centric relation and VDO

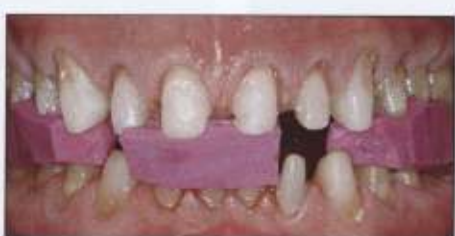

Figure 16: The mandibular anterior teeth were prepared and a new anterior bite record was taken utilising the new posterior bite records to maintain centric relation and VDO

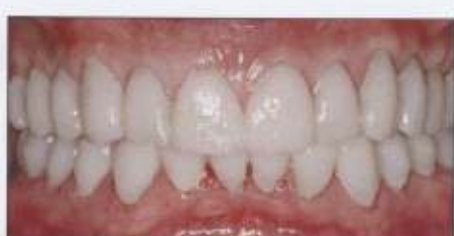

Figure 17: Final provisional restorations fabricated in three sections

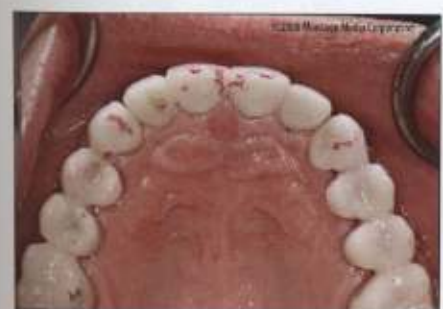


Figure 18: Occlusal equilibration in centric relation establishing canine and protrusive guidance

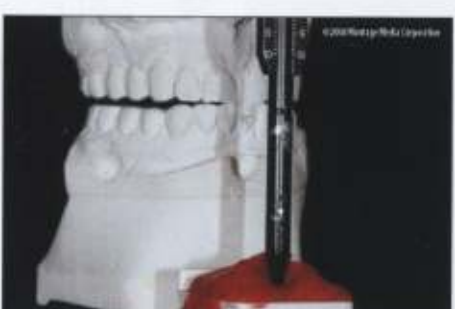

Figure 19: Fabrication of a custom incisal guide table

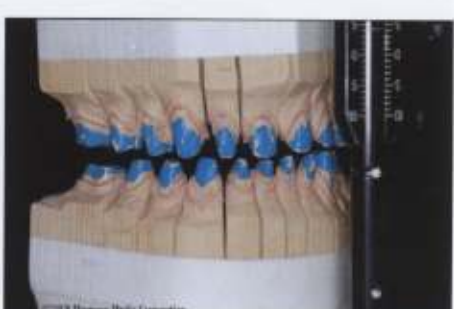

Figure 20: The mandibular preparation model was then mounted against the maxillary preparation model with the first set of bite records

manipulation and a leaf gauge (Long 1970, McKee 2005). Both methods resulted in no reported tension or tenderness and revealed first point of contacts on the second molars, with a forward slide into the maximum intercuspation position.

Impressions for study casts were then made, along with a centric relation occlusal record utilising the leaf gauge and a facebow transfer (Figure 5) (Long 1970, McKee 2005, Fenlon and Woelfel 1993). Following the mounting of the study casts, it became apparent that by seating the condyles in a centric relation position, the second molars were in premature contact and there was sufficient space gained to restore the anterior teeth to the proper aesthetic length (Figure 6).

### Treatment planning

Following periodontal consultation, it was determined that all of the second molars

would be extracted due to advanced bone loss. Osseous surgery would follow in all four posterior quadrants, as would aesthetic crown lengthening in the anterior region. Due to the advanced wear of the remaining teeth, the treatment plan involved full-coverage restorations on all teeth. The presence of sclerotic dentin and the possibility of continued clenching and/or bruxism established the need for cemented, as opposed to adhesive, restorations (Tay and Pashley 2004, Kwong et al 2000). For long-term predictability, the author selected porcelain-fused-to-metal (PFM) restorations. Zirconia crowns would also have represented an acceptable choice.

Once the treatment plan was accepted, an intraoral composite mockup was performed and photographed to establish an ideal length for the central incisors from an aesthetic standpoint (Figure 7). These images and the measured length of the maxillary central inci-

sors were then communicated to the laboratory technician to aid in the fabrication of a full-mouth diagnostic wax-up, which would be completed with the understanding that the second molars were to be removed and that aesthetic crown lengthening procedures would be performed to raise the gingival tissues in the anterior region (Figure 8). Prior to waxing the case, the ceramist fabricated a centric relation anterior index that would maintain the centric relation position at the desired VDO during the preparation phase (Figure 9). This index can be made from hard laboratory putty or GC pattern resin.

### Tooth preparation

Following a two-month period of periodontal healing and maturation, the patient was scheduled for appointments on two consecutive days to prepare first the maxillary, then the mandibular arches. On the first day, the

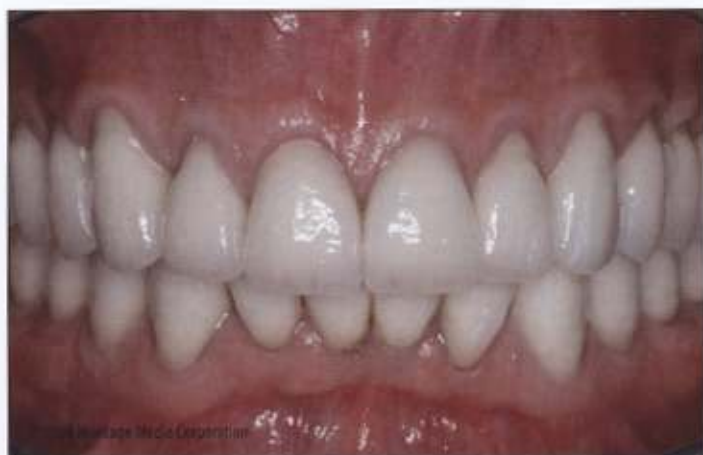

Figure 21: The provisionals were removed and the definitive crowns were tried in and evaluated for aesthetics, occlusion and phonetics

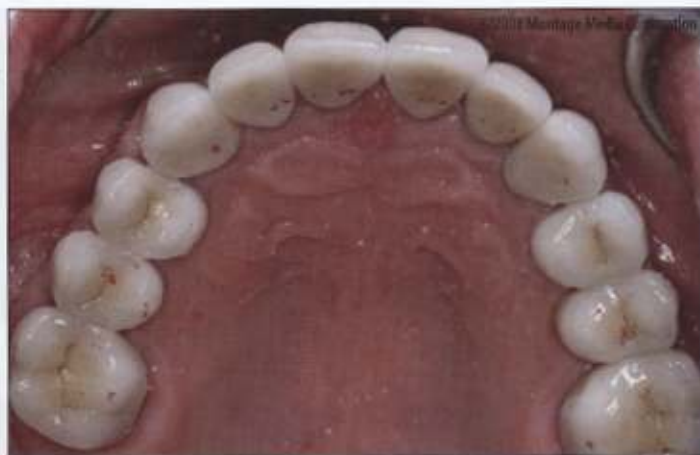

Figure 22: View of the completed maxillary restorations. Guidelines established through provisionalisation ensured minimal adjustments were needed

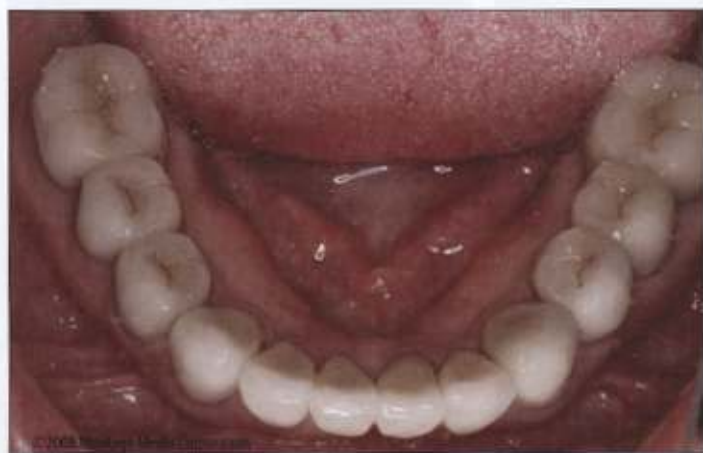

Figure 23: Occlusal view of the aesthetic final restorations seated on the mandibular arch

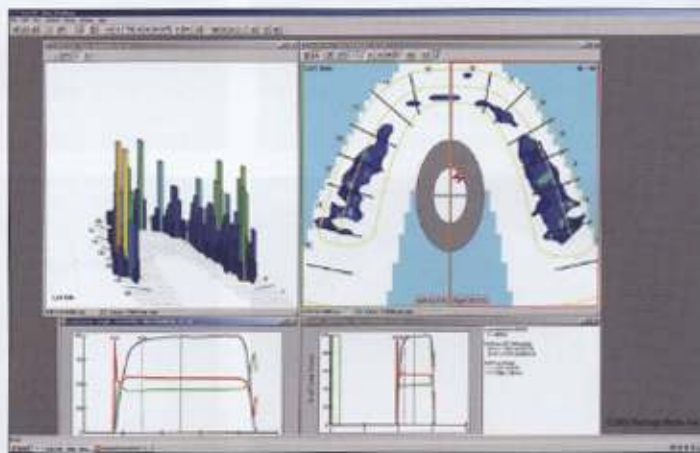


Figure 24: Final equilibrium of the case was accomplished with a computerised occlusal analysis (T-scan III, Tekscan, Boston, MA)

author utilised the centric relation index and measured from the marginal tissue of teeth #9(21) through #24(31)—gaining 2.38 mm of anterior space by simply having the condyles seated in centric relation. This anterior opening was accomplished without appreciably stretching the elevator muscles (Figures 10 and 11). Preparation of the maxillary right and left posterior teeth was then performed using the index to confirm clearance. With the index in place, posterior bites were taken utilising a

rigid bite-registration material (i.e. Futar-D, Roydent Dental Products, Johnson City, TN) (Figure 12).

The index was then removed, and the anterior teeth were prepared utilising the posterior bite records to verify clearance. Following completion of the anterior preparations, an anterior bite was obtained with the posterior bite records in place. By systematically recording the posterior bite with the centric index in place and then the anterior bite with the pos-

terior bites in place, the centric relation and vertical dimension position were maintained (Figure 13).

A full-arch polyether impression (Perma-soft, Garant-L, 3M ESPE, St. Paul, MN) was then taken, followed by the fabrication of provisional restorations (Luxatemp, Zenith/DMG, Englewood, NJ) created in three sections: two posterior sections from molar to first premolar, and an anterior section from canine to canine. Since the maxillary arch was prepared on the

**Dr Jay Lerner is a Senior Instructor for the Aesthetic Advantage Hands-on Continuum. This five-day course will be held this year in London on Friday 11 - Sunday 13 July and Friday 18 - Saturday 19 July. Dr Lerner will also be a speaker at next year's World Aesthetic Congress. For further information and to book your places, please call 0800 371652, visit [www.independentseminars.com](http://www.independentseminars.com) or email: [seminars@fmc.co.uk](mailto:seminars@fmc.co.uk)**

**independent  
seminars**

first day, occlusion was adjusted against the provisionals through equilibration of the mandibular teeth (Figure 14).

During the second visit, the maxillary provisional restorations were removed and the anterior bite record from day one was inserted to hold the centric relation and vertical dimension while the mandibular posterior teeth were prepared. Following bilateral preparation of mandibular posterior teeth, bite records were taken with the anterior bite record in place (Figure 15). The mandibular anterior teeth were then prepared utilising the posterior bite records to check clearance, and a new anterior bite record was taken (Figure 16).

A polyether final impression was then made, and mandibular provisional restorations were fabricated from the index of the diagnostic waxup. As with the maxillary provisionals, the mandibular provisionals were fabricated in three sections (Figure 17). The provisional restorations were subsequently equilibrated to establish maximum intercuspation in centric relation along with canine guidance and anterior coupling in protrusive guidance (Figure 18).

Once the provisional restorations were equilibrated and the aesthetics and phonetics were deemed satisfactory, an occlusal bite record was taken of the maxillary and mandibular provisional restorations. The maxillary posterior sections were removed and, with the anterior section still in place, posterior bite records were taken. The anterior section was then removed and, with the posterior bite records in place, an anterior bite record was taken.

Impressions of the provisional restorations were made, and a facebow recording was taken of the maxillary provisionals. Utilising the facebow, the maxillary provisional model was mounted on the articulator; the mandibular model was then mounted using the occlusal bite record of the provisionals against each other. The ceramist was thus able to fabricate a custom incisal guide table (Figure 19). A custom incisal guide table, as described by Dawson, allows the ceramist to reproduce the anterior guidance established in the mouth with the provisional restorations (Dawson 2006). The protrusive path and lateral excursions were recorded in pattern resin on a flat guide table by movement of the articulator pin in the unset resin (Dawson 2006).

Once the incisal guide table was fabricated, cross mounting began. The maxillary preparation model was mounted against the mandibular provisional restorations utilising the third set of bite records. The mandibular

preparation model was next mounted against the maxillary preparation model with the first set of bite records (Figure 20).

Along with digital photographs of the preparations and provisional restorations, the ceramist had all the information necessary to fabricate the definitive restorations. A putty index was made from the provisional model to confirm the exact length and shape for the final restorations, while the custom guide table provided information on the shape of the lingual aspects and the path taken for the canine and protrusive guidance.

### Definitive restorations

Following a three-week period, the provisional restorations were removed, the case was tried in, and then evaluated for aesthetics, occlusion, and phonetics. Since the ceramist followed the guidelines of the provisional restorations, minimal adjustments were necessary at this stage (Figures 21-23). Final equilibration of the case was accomplished with a leaf gauge and a computerised occlusal analysis system (i.e. T-Scan III, Telescan, Boston, MA) (Figure 24) (Kerstein and Wilkerson 2000, Kerstein 1992).

### Conclusion

Severe wear cases present many challenges to the restorative dentist, including gaining the space to create restorations to satisfy the patient's aesthetic desires, while also fulfilling occlusal and functional parameters that are essential for long-term success. The case presented has demonstrated that the required space may be obtained by seating the condyles in centric relation position. The maintenance of severe wear cases can be ensured by the development of proper anterior guidance that allows for posterior disclusion within the patient's envelope of function. Taking this guidance into account during provisionalisation ensures minimal adjustments in the definitive restorations and a greater long-term predictability of the case.

### Acknowledgement

The author mentions his gratitude to Dr. Robert Holt for his expertise in managing the periodontal aspect of this case and Mr. Jason Kim, Oral Design, New York, NY for the laboratory fabrication of the restorations depicted. Figures 1 and 2 appear courtesy of Dr. Michael Sesemann. The author declares no financial interest in any product referenced herein.

This article was kindly reproduced from *Practical Proceedings Aesthetic Dentistry* 2008; 20(2):81-87

### References

- Addy M, Shellis RP. Interaction between attrition, abrasion and erosion in tooth wear. *Monogr Oral Sci* 2006;20:17-31.
- Beith N, Sharon E, Lipovetsky M, Smidt A. Wear and different restorative materials—A review. *Refuat Hapeh Vehashshayim* 2006;24(3):6-14.
- Dahl BL, Carlsson GE, Ekfeldt A. Occlusal wear of teeth and restorative materials. A review of classifications, etiology, mechanism of wear, and some aspects of restorative procedures. *Acta Odontol Scand* 1993;51(5):299-311.
- Dawson PE. *Functional Occlusion: From TMJ to Smile Design*. St. Louis, MO: Mosby; 2006:432-433.
- Fenlon Mr, Woelfel JB. Condylar position recorded using leaf gauges and specific closure forces. *Int J Prosthodont* 1993;6(4):402-408.
- Grippio JO, Simring M, Schreiner S. Attrition, abrasion, corrosion and abfraction revisited. A new perspective on tooth surface lesions. *J Am Dent Assoc* 2004;135(8):1109-1118.
- Kerstein RB, Wilkerson DW. Locating the centric relation prematurity with a computerized occlusal analysis system. *Compend Contin Educ Dent* 2002;22(6):525-528.
- Kerstein RB. Disocclusion time-reduction therapy with immediate complete anterior guidance development to treat chronic myofascial pain-dysfunction syndrome. *Quint Int* 1992;23(11):735-747.
- Kwong SM, Tay FR, Yip HK, et al. An ultrastructural study of the application of dentine adhesive to acid-conditioned sclerotic dentine. *J Dent* 2000;28(7):515-528.
- Litorjua LA, Andreana S, Bush PJ, Cohen RE. Tooth wear: Attrition, erosion, and abrasion. *Quint Int* 2003;34(6):435-446.
- Long JH Jr. Location of the terminal hinge axis by intraoral means. *J Prosthet Dent* 1970;23(1):11-24.
- Mckee JR. Comparing condylar positions achieved through bimanual manipulation to condylar positions achieved through masticatory muscle contraction against an anterior deprogrammer: A pilot study. *J Prosthet Dent* 2005;94(4):389-393.
- Nell P. Trauma from occlusion. Restorative concerns. *Dent Clin North Am* 1995;39(2):335-354.
- Sesemann MR. Enhancing facial appearance with aesthetic dentistry, centric relation, and proper occlusal management. *Pract Proced Aesthet Dent* 2005;17(9):615-620.
- Spear FM. Approaches to vertical dimension. *Adv Esthet Interdiscip Dent* 2006;2(3):2-12.
- Tay FR, Pashley DH. Resin bonding to cervical sclerotic dentin: A review. *J Dent* 2004;32(3):173-196.
- Verrett RG. Analyzing the etiology of an extremely worn dentition. *J Prosthodont* 2001;10(4):224-233.