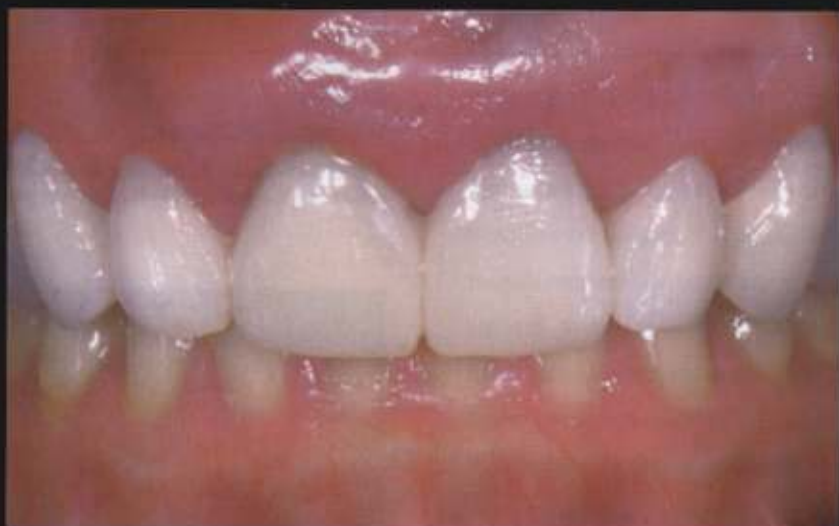

CUSTOMIZED PROVISIONAL ABUTMENT AND PROVISIONAL RESTORATION FOR AN IMMEDIATELY-PLACED IMPLANT

Gerard J. Lemongello, Jr, DMD*



The use of immediate implant placement and immediate provisionalization techniques are paramount to the maintenance for aesthetic hard and soft tissue structures. This is particularly important when implant-supported restorations are utilized in the aesthetic zone. A purpose of the custom-fabricated provisional abutment and restoration is to guide the hard and soft tissue response during healing. This case presentation depicts the prosthetic technique used by the author to create the final tissue contours and emergence profile for the final restoration.

Learning Objectives:

This article explores provisionalization immediately following surgical implant placement. Upon reading this article, the reader should:

- Understand how the immediate placement of a custom provisional abutment guides tissue healing.
- Recognize how provisionalization can preserve hard and soft tissues and help minimize the duration of treatment.

Key Words: provisional, implant, abutment, prosthetic, immediate, customized

*Private practice, Palm Beach Gardens, FL

Gerard J. Lemongello, Jr., DMD, 5602 PGA Blvd., Ste. 201, Palm Beach Gardens, FL 33418
Tel: 561-627-9000 • E-mail: lernerlemongello@aol.com

Dental implants, as a result of their excellent success rates and advantages over fixed or removable methods,¹⁹ have for many clinicians become the optimal treatment for replacing missing teeth. The ability of implants to conserve adjacent tooth structures often sacrificed by prosthodontic solutions, and their capacity to maintain the existing alveolar bone are noted among the principle benefits of implant-supported restorations.¹⁴

Over the past several decades, researchers have endeavored to further improve clinical outcomes achieved with dental implants, focusing on the hard and soft tissues that must exist or be developed throughout implant therapy.^{5,6} Immediate implant placement evolved from these goals and has been documented to reduce tissue loss following tooth extraction;^{7,11} the use of customized provisional abutments and immediate provisionalization have shown similar promise for their ability to provide optimal aesthetics and to shape the tissue response during the healing phase.¹² While the literature contains previous reports demonstrating the use of a custom-fabricated provisional abutment and restoration after a traditional healing period to guide tissue response and improve

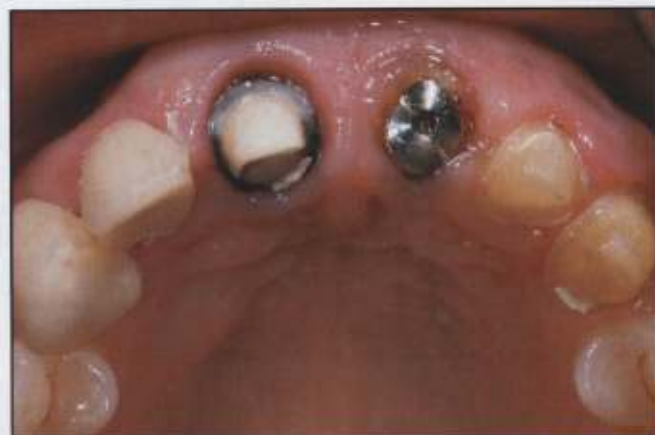

Figure 2. Appearance of the surgical healing screw in place 24 hours following the immediate implant surgery.

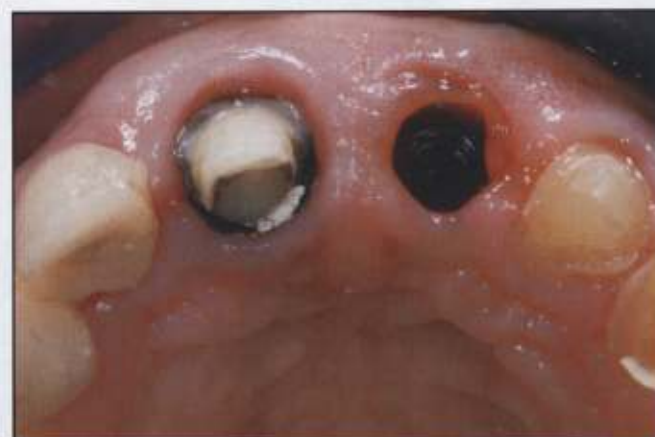

Figure 3. The surgical healing screw was removed after 24 hours to permit try-in of the provisional abutment.

implant aesthetics,¹³ the approach that follows will explore provisionalization immediately following surgical implant placement.

Case Presentation

A 52-year-old female patient presented with the chief complaint of a loose crown on tooth #9(11) (Figure 1). As a result of trauma decades previously, this tooth had required endodontic treatment, placement of a post and core, and a full-coverage crown restoration. Since that time, endodontic re-treatment and an apicoectomy had

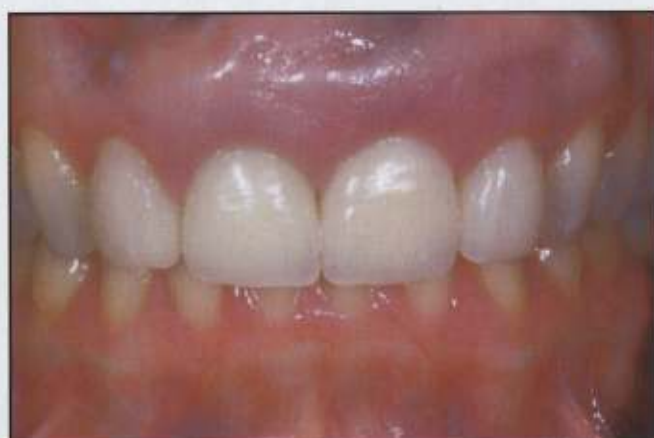

Figure 1. Preoperative appearance of patient demonstrated short clinical crowns and a discolored, uneven appearance of the dentition.

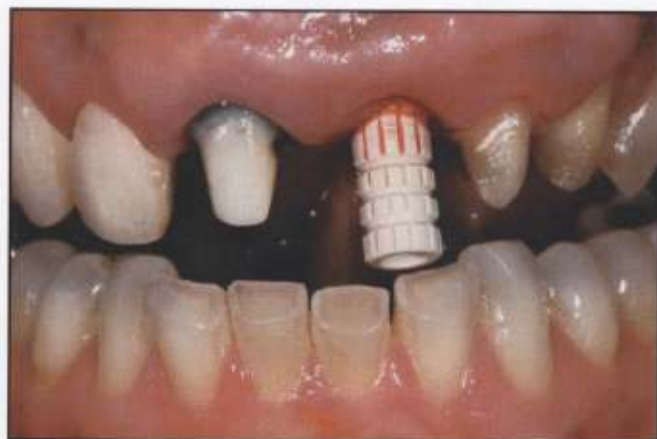

Figure 4. A provisional abutment was tried in to permit assessment of customization required for proper tissue support.

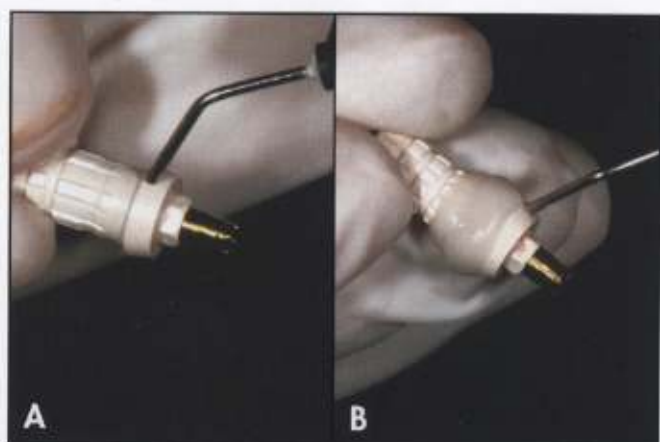


Figure 5A. Flowable composite resin was added to the provisional abutment. **5B.** The contour of the abutment was adjusted for the desired tissue contouring.

been performed to maintain the health of the tooth. Clinical and radiographic examination revealed the probable fracture of the endodontic post and the root of tooth #9. The patient also desired treatment for her excessive gingival display and short clinical crown length.

Treatment Planning and Implant Placement

Comprehensive restorative treatment was suggested to replace the hopeless tooth #9 and enhance aesthetics of the patient's anterior maxillary dentition. Although this plan would address the patient's reclined vertical tooth

position and resultant deep bite—with a restricted envelope of function that caused wear of the mandibular anterior teeth—she desired a more conservative restorative approach. As teeth #6(13) through #11(23) would be treated at this time, the patient was counseled that additional treatment would be necessary in the future to restore proper anterior guidance.

In order to facilitate analysis of occlusion, models were mounted on an articulator in centric relation with a facebow transfer. From the models, a putty matrix was created to aid in the fabrication of the provisional restoration. Spanning teeth #6 through #11, the provisional restoration was fabricated using the putty matrix and provisional resin (ie, Luxatemp, Zenith/DMG, Englewood, NJ). It would act as the surgical guide for implant placement and crown lengthening surgery.

Tooth #9 was scheduled for extraction, bone grafting, and immediate placement of an internal connection implant (eg, Certain Prevail, Implant Innovations, Inc., Palm Beach Gardens, FL). A platform switching technique was selected to preserve bone surrounding the implant;^{14,15} this would be followed by immediate fabrication of a custom provisional abutment to guide tissue healing and provide the restoration with proper tissue

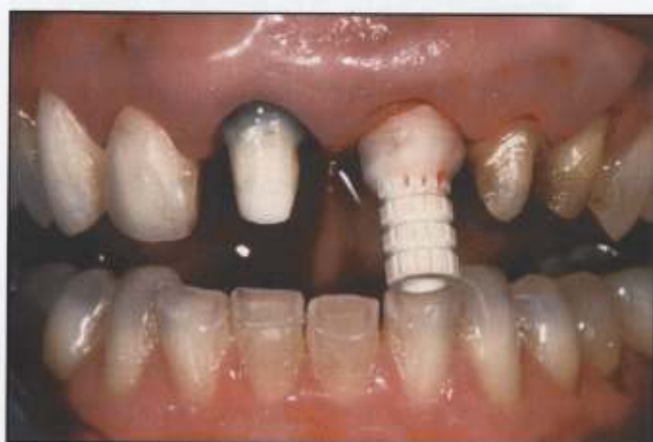

Figure 6. The provisional abutment, with the added composite, is tried in again to assess tissue support.

support and a natural emergence profile.¹ The patient was then appointed for the provisionalization of teeth #6 through #11, which would assist in the aesthetic design and act as surgical guide for implant and crown lengthening surgery.

Provisionalization Technique

Following successful tooth extraction and subsequent bone grafting procedures over a four month period, the alveolar bone was adequately developed for implant placement. One day following implant placement, the patient presented for fabrication of an immediate customized provisional abutment and provisional restorations (Figure 2). The surgical healing screw was removed, and a provisional abutment (ie, ProFormance, 3i, Palm Beach Gardens, FL) was tried in to assess the need for custom alteration of the abutment to achieve proper soft tissue support and emergence profile (Figures 3 and 4).

The abutment was removed and a flowable composite material (eg, Luxaflow, Zenith/DMG Englewood, NJ) was added to the subgingival area to initiate formation of the subgingival collar. The composite was added with a slightly greater contour than observed during abutment try-in (Figure 5). The provisional abutment was subsequently tried in again to assess the tissue support and subgingival emergence contour of the added material (Figure 6). The abutment was then removed and shaped to ideal tissue support and subgingival contour (Figure 7).

Once the proper tissue contour was established, the provisional abutment was seated and prepared chair-side according to the fundamentals of traditional prosthetic crown preparation and contour. A shoulder margin was prepared 0.5 mm subgingival to the free gingival margin to ensure margin placement would not be visible in the definitive implant-supported restoration (Figure 8). The abutment was again removed and inspected

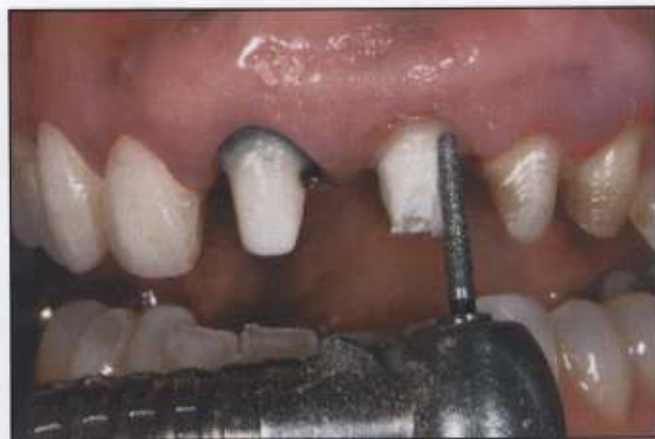

Figure 7. A shoulder margin was prepared according to traditional prosthodontic procedures.

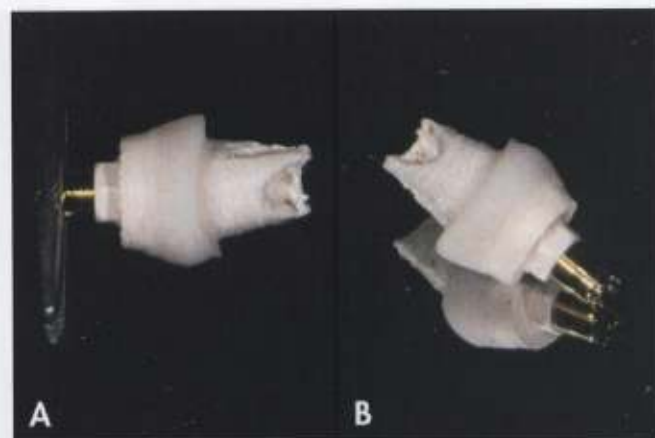


Figure 8A. The abutment was finalized prior to seating. **8B.** Adjustments were made to the abutment's design prior to provisionalization.

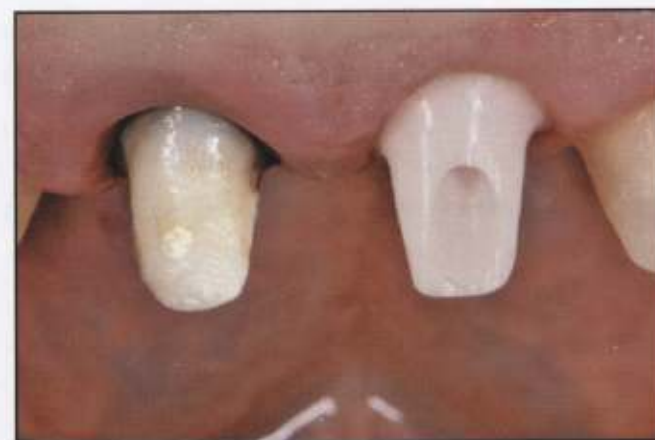

Figure 9. Facial view of the abutment during try-in. Note the maintenance of the aesthetic gingival contours.

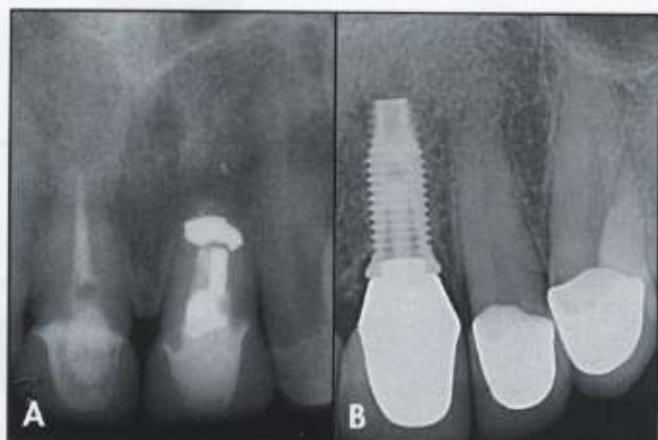


Figure 10A. Preoperative radiograph of the anterior maxilla.
10B. Radiograph taken following implant placement.

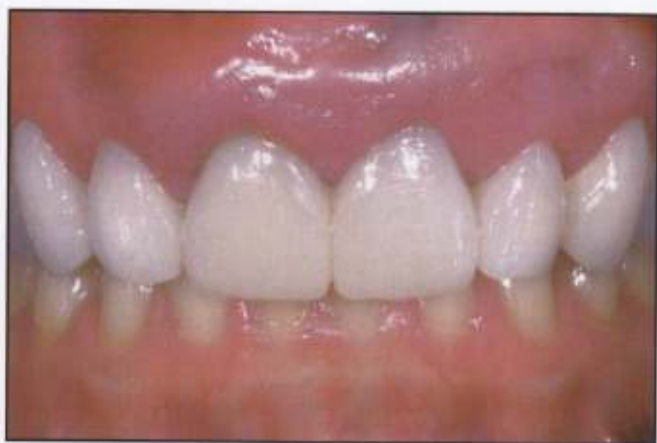

Figure 11. Appearance of the provisional restoration in place. Note the aesthetic integration and maintenance of the tissue support.

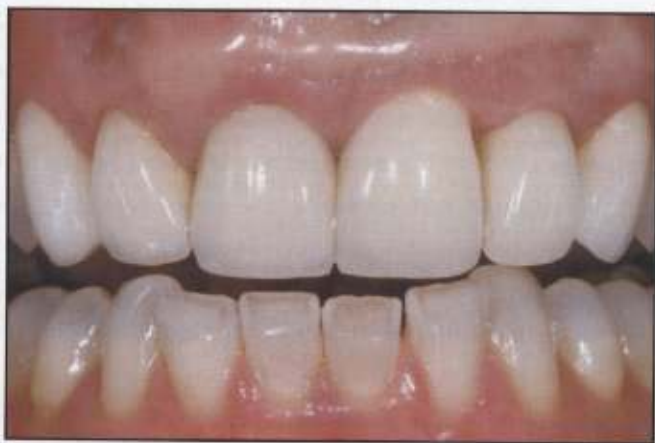

Figure 12. Appearance of the final ceramic try-in demonstrated the aesthetics achieved prior to tissue maturation.

for any additional refinements necessary prior to placement (Figure 9). The abutment screw was placed and torqued to the proper tightness.

The provisional restoration was then fabricated in the traditional manner using the original putty matrix that was created during the diagnostic phase. Once the provisional restoration was positioned and occlusion was verified, the patient was dismissed and the appropriate healing time was allowed prior to final impression making for fabrication of the definitive restorations (Figures 10 and 11).

Restorative Phase

The implant was allowed to osseointegrate for approximately six months, after which the patient presented to initiate final restoration. A customized zirconium abutment was fabricated in order to capture the identical contours of the custom-fabricated provisional abutment. During final impression-making, the provisional was removed and the abutments were cleaned. A polyether impression of the custom provisional abutment was then captured to provide the laboratory technician with an accurate model with which to construct the zirconium abutment. The custom-fabricated provisional abutment was then removed, and a stock, closed-tray impression coping was placed. A second polyether impression of the five natural teeth and impression coping was made immediately. The impression coping was then removed, and a laboratory analog was attached. This impression coping-analog complex was inserted into the impression for verification. The custom-fabricated provisional abutment was then returned to position and secured. A facebow transfer and anterior stick bite were recorded in MI. Impressions of the provisional and opposing mandibular arch were captured in alginate after the provisional was cemented. The two polyether impressions, facebow transfer, stick bite, mandibular and provisional stone models, and a set of photographs of the stump shade and provisional were then sent to the lab-

oratory, along with complete instruction for fabrication of the zirconium implant abutment (ie, Atlantis, Zimmer Dental, Carlsbad, CA) and zirconium ceramic crowns to precisely match the provisional. Zirconia abutments were chosen due to their precise fit and excellent results in the aesthetic zone; these restorations eliminate the appearance of metal margins and require no modifications prior to delivery.

Definitive Restorations

The final restorations were evaluated on the working model for accuracy. Once proper fit and occlusion were established using an articulating device, the patient's provisional restoration and custom-fabricated provisional abutment were removed, and the zirconium abutment was placed on the implant fixture, secured with a gold screw, and torqued to 20 N. Digital radiography was used to verify fit and integration. The zirconium ceramic crowns were tried in and inspected for accuracy, contour, and shade match. Once the restorations were determined to be acceptable, the screw access hole was filled with a polyvinylsiloxane bite registration material, and the crowns were cemented. The occlusion was adjusted to provide anterior stops of even intensity, with anterior and incisal guidance (Figure 12).

Conclusion

The placement of dental implants as a permanent, fixed, aesthetic alternative, can allow the clinician to predictably restore patients suffering from partial or complete edentulism. While numerous treatment techniques have been developed to assist in the preservation of hard and soft tissues, the clinician's ultimate goal should be to preserve these tissues, and minimize the duration of treatment. The use of a custom-fabricated provisional, a customized provisional abutment, and a custom-fabricated final abutment with the appropriate anatomical contours can allow the creation of imperceptible restorations that accurately

mimic nature. As the clinician's restorative armamentarium continues to expand based on evolving technological advancements, the ability to deliver functional and aesthetic results with predictable longevity will also expand, allowing optimal results following implant placement.

Acknowledgments

The author mentions his gratitude to Dr. Robert Holt of West Palm Beach, FL, for the depicted implant placement as well as his assistance in the manuscript development. The author declares no financial interest in any of the products mentioned herein.

References

1. Kan JYK, Rungcharassaeng K. Immediate placement and provisionalization of maxillary anterior single implants: A surgical and prosthetic rationale. *Pract Periodont Aesthet Dent* 2000;12(9):817-824.
2. Spear FM. Maintenance of the interdental papilla following anterior tooth removal. *Pract Periodont Aesthet Dent* 1999;11(1):21-28.
3. Tamow DF, Magner AVV, Fletcher P. The effect of the distance from the contact point to the crest of the bone on the presence or absence of the interproximal dental papilla. *J Periodontol* 1992;63(12):995-996.
4. Kan JYK, Rungcharassaeng K. Immediate placement and provisionalization of maxillary anterior implants: 1-year prospective study. *Int J Oral Maxillofac Impl* 2003;18(1):31-39.
5. Touati B, Guez G, Saadoun A. Aesthetic soft tissue integration and optimized emergence profile: Provisionalization and customized impression coping. *Pract Periodont Aesthet Dent* 1999;11(3):305-314.
6. Wolfe PS. Single-tooth replacement in the aesthetic zone with immediate provisionalization: Fourteen consecutive case reports. *Pract Periodont Aesthet Dent* 1998;10(9):1107-1114.
7. Lazzara RJ. Immediate implant placement into extraction sites: Surgical and restorative advantages. *Int J Periodont Rest Dent* 1989;9(5):333-343.
8. Schropp L, Kotropoulos L, Wenzel A. Bone healing following immediate versus delayed placement of titanium implants into extraction sockets: A prospective clinical study. *Int J Oral Maxillofac Impl* 2003;18(2):189-199.
9. Marton D, Jaffin R, Weber HP. Immediate restoration and loading of dental implants: Clinical considerations and protocols. *Int J Oral Maxillofac Implants* 2004;19(Suppl):103-108.
10. Rosenquist B, Grenthe B. Immediate placement of implants into extraction sockets: Implant survival. *Int J Oral Maxillofac Impl* 1996;11(2):205-209.
11. Schwartz-Arad D, Chaushu G. The ways and wherefores of immediate placement of implants into fresh extraction sites. A literature review. *J Periodontol* 1997;68(10):915-923.
12. del Castillo RA. Immediate provisionalization of a single-tooth implant with a temporary cylinder in one surgical appointment. *Pract Proced Aesthet Dent* 2006;18(5) (suppl):3-5.
13. Lemongello GJ Jr. Immediate custom implant provisionalization: A prosthetic technique. *Pract Proced Aesthet Dent* 2007;19(5):273-279.
14. Lazzara RJ, Porter SS. Platform switching: A new concept in implant dentistry for controlling postrestorative crestal bone levels. *Int J Periodont Rest Dent* 2006;26(1):9-17.
15. Baumgarten H, Cocchetto R, Testori T, et al. A new implant design for crestal bone preservation: Initial observations and case report. *Pract Proced Aesthet Dent* 2005;17(10):735-740.